CASE REPORT

Airway Management in Tracheobronchopathia Osteochondroplastica

Authors:
Dr Nisha Rajmohan, Dr Arunima Mohan, Dr Suresh G Nair, Dr Babu Sankar J
Astermedicity Kochi, Kerala.

Submitted: 12 Apr 2025
Revised: 14 Apr 2025
Accepted: 20 Apr 2025
Published: 05 May 2025

Access This Artile Online

Website:
theanaesthesiologist.com

ABSTRACT

Tracheobronchopathia osteochondroplastica (TO), a rare large airway disorder, is a rare cause of unanticipated difficult airway. A 36years old male, known case of Tracheobronchopathia osteochondroplastica , was posted for laparoscopic cholecystectomy. CT thorax taken in 2019 showed nodular calcifications in tracheal wall and bilateral main stem bronchi. Upper Airway examination was normal. Patient was induced and endotracheal tube was placed just below the vocal cords and Fibreoptic bronchoscope was passed through and tube was positioned in such a way that nodules were avoided and unobstructed ventilation was confirmed. Intraoperative period was uneventful, check bronchoscopy postoperatively showed no bleeding/edema. Patient was reversed and extubated. TO patients experience unexpected difficulties in subglottic intubation, which creates a difficult situation. Assessment of the subglottic airway should also be taken seriously in order to avoid unexpected intubation impediment.

Keywords: Tracheobronchopathia osteochondroplastica, intubation, fiberoptic bronchoscopy, airway assessment, subglottic airway assessment, fiberoptic bronchoscopy-assisted tracheal intubation

Introduction:

Tracheobronchopathia osteochondroplastica (TO) is a very rare cause of unanticipated difficult airway. (1) Trachea and mainstem bronchi narrowed by projections of submucosal nodules which can be either cartilaginous or ossified. (1,2) Therefore, the anesthetist faces difficulty in passing the endotracheal tube beyond the glottis. (1) This condition is either asymptomatic or is misdiagnosed as bronchial asthma. (3) Here we present the airway management of a known case of TO for a laparoscopic cholecystectomy.

Case report:

36 years old male patient was posted for laparoscopic cholecystectomy. He was a known case of Tracheobronchopathia osteochondroplastica (TO) diagnosed in 2016.He was treated case of pulmonary tuberculosis in 2019. In 2021 he had Acute Necrotizing Pancreatitis (modified CT severity- 10), resolved walled off pancreatic necrosis. He developed acute respiratory distress syndrome and was tracheostomized at that time. During the present admission he presented with fever, tachycardia, tiredness, grade 1 exertional dyspnea and was on Ursodeoxycholic Acid, pancreatin, pantoprazole and N acetylcysteine.

Echocardiogram showed mitral valve prolapse, mild mitral regurgitation, mild tricuspid regurgitation trivial, aortic regurgitation, good left ventricular function. CT thorax taken at that time showed nodular calcifications in tracheal wall
and bilateral main stem bronchi suggestive of TO. Rest of airway examination was normal.

High risk informed consent, possibility of difficult intubation was explained to patient and relatives. Patient was planned for general anesthesia with endotracheal intubation. All monitors attached according to ASA standards .20g cannula placed over right upper limb. Difficult airway cart was kept stand by. Intraarterial 20g insyte was placed for arterial pressure monitoring and blood gas sampling in case the requirement arises. Patient induced with Midazolam 2mg, fentanyl 150mcg, propofol100 mg and succinyl choline100 mg. Laryngoscopy done, vocal cords were visualized easily (CL grade: 2) 7. 0mm ETT (lubricated well with lignocaine 2% jelly) was passed just below vocal cords. and fixed at 20 cm. Bilateral air entry confirmed. Fiberoptic bronchoscope (FOB) was passed through endotracheal tube. Mucosal irregularities were seen in tracheobronchial tree with calcified nodules over the trachea up to carina. Left main bronchus partially obstructed. Calcified nodules were also noted in left and right main bronchus. The tube was positioned under vision in such a way at 21cm that the nodules were avoided. and we confirmed unobstructed ventilation. We also made sure that the cuff was intact and that nodules do not injure the cuff and produce a leak. Intraoperative period was uneventful. Blood loss was minimal. Total fluid given was 600 ml Ringer lactate. Check bronchoscopy at the end of surgery confirmed the absence of bleeding. Patient was reversed with neostigmine 2.5mg and glycopyrrolate 0.4mg and was extubated. Multi modal analgesia was given with intravenous paracetamol 1gm sixth hourly and Tramadol 50mg given twice daily. Patient had an uneventful recovery.

Discussion:

Tracheobronchopathia osteochondroplastica (TPO) first reported by Rokitansky in the year 1855, is benign condition of unknown aetiology affecting the lower part of the trachea and the upper part of the main bronchi. [3]

Since it was a laparoscopic procedure with controlled ventilation with an anticipated difficult airway, we decided to go ahead with endotracheal intubation. The patient had a previous history of tracheostomy and decannulation so subglottic stenosis can be expected. Previous CT showed multiple lesions in the trachea and main stem bronchus. (Figure 1) Severe narrowing of the airway above carina was not seen. We decided to go ahead with smaller size well lubricated endotracheal tube after confirming the ability to mask ventilate the patient. The endotracheal tube was passed through the vocal cords fixed at 20 cm so that none of the projections could damage the tube or produce obstruction. The bronchoscopy that followed confirmed numerous nodules on the trachea and mainstem bronchus projecting into the lumen. (Figure 2) We found that left main bronchus was partially obstructed. However, we could get air entry on the left side and there was no significant desaturation. So, the tube was pushed in and positioned at 21cm so that cuff and the distal end was free of the cartilaginous projections. Doing a bronchoscopic positioning helped in preventing injury, bleeding and cuff damage. Checking bilateral air entry after each change in position is all the more important in these cases as tube migration can result in difficulty in ventilation. Various techniques advised for management of airway in TO include inserting ETT with rotation into trachea, selection of normal tube instead of spiral one, dilation and removal of obstructive spurs preoperatively (prevent ETT cuff rupture), use of supraglottic airway devices when feasible. [2,3,4] Awake intubation may be necessary if there is a risk of “can’t intubate, can’t ventilate” anticipated situation. [5]

Discussion:

TO is a very rare cause of difficult subglottic intubation which can result in confusion and panic. Hence, we decided to report this rare condition which can affect the airway management beyond the glottis. Difficult airway guidelines focus mainly on the supraglottic causes of difficult airway. Preoperative CT scan is usually not a part of preoperative investigations as a result of which this diagnosis may be missed. In a known case of TO we suggest a preoperative CT to plan the airway management. FOB, smaller sized tubes, supraglottic airway devices are some of the essentials for the airway management.

References:

1.Huang L, Wang J, Chen S, Fang X. Study and reflection on anesthesia for tracheobronchopathia osteochondroplastica.J Int Med Res. 2020 ;48(11): 300060520971498. doi: 10.1177/0300060520971498.

2. Sakaguchi Y, Matsumoto K, Nishioka K, Iizuka N, Hirayama Y, Kitaoka A, Tanimura K, Takahashi KI, Kato M Bronchoscopic Surgery for a Solitary Tracheal Tumor of Tracheobronchopathia Osteochondroplastica..Ann Thorac Surg. 2020 ;109: e419-e421. doi: 10.1016/j.athoracsur.2019.09.014.

3.Tracheobronchopathia osteochondroplastica: A rare case of misdiagnosis and difficult intubation. Chaurasia S, Ray S, Chowdhury S, Balaji B.J R Coll Physicians Edinb. 2022; 52:54-6. doi: 10. 1177/14782715221088978.

4.Tracheobronchopathia osteochondroplastica and difficult intubation: case report and perioperative recommendations for anesthesiologists.Warner MA, Chestnut DH, Thompson G, Bottcher M, Tobert D, Nofftz M.J Clin Anesth. 2013; 25:659-61. doi: 10. 1016/j.jclinane.2013.05.010.

5. Takamori R, Shirozu K, Hamachi R, Abe K, Nakayama S, Yamaura K. Intubation Technique in a Patient with Tracheobronchopathia Osteochondroplastica. Am J Case Rep. 2021 18;22: e928743. doi: 10.12659/AJCR.928743.

Figure 1: Coronal section of CT chest showing irregular thickening and nodularity of tracheal artilages involving carina and bilateral bronchi. Partial obstruction of left bronchi also seen

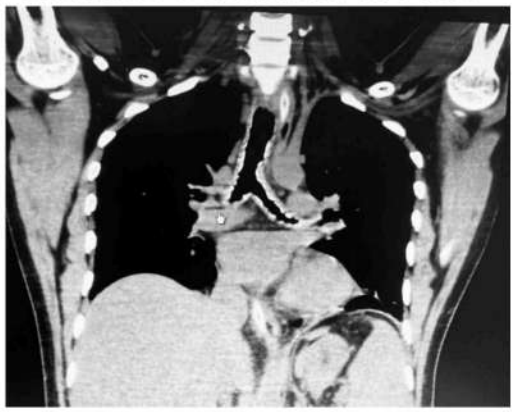

Figure 2: Fiberoptic bronchoscopic image of the patient showing multiple irregular ossified submucosal nodules sparing the posterior membrane.

